

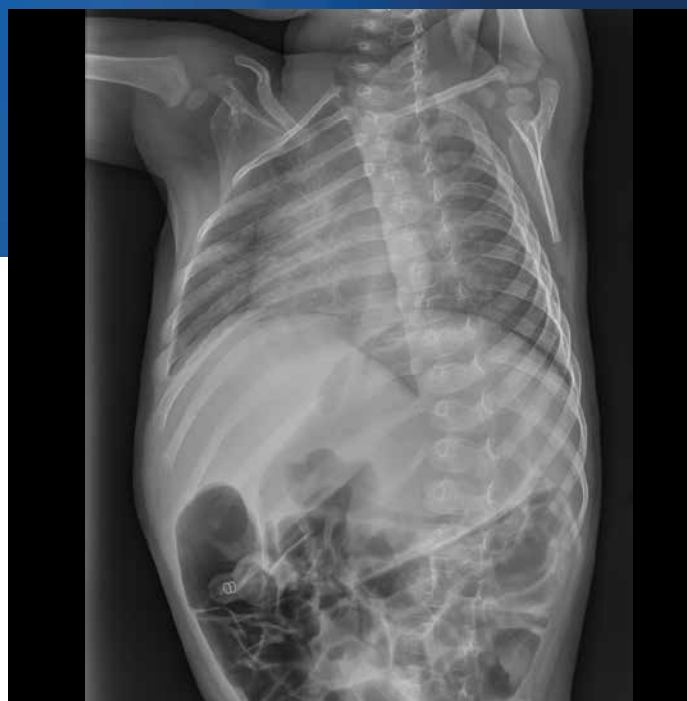RTI Press

Conference Proceedings

September 2017

**Proceedings of the
International Forensic
Radiology Research Summit
May 10–11, 2016,
Amsterdam, The Netherlands**

Nicole S. Jones, Jeri D. Roper-Miller, Heather Waltke,
Danielle McLeod-Henning, Danielle Weiss, and
Hannah Barcus



RTI Press publication CP-0005-1709

This PDF document was made available from www.rti.org as a public service of RTI International. More information about RTI Press can be found at <http://www.rti.org/rtipress>.

RTI International is an independent, nonprofit research organization dedicated to improving the human condition by turning knowledge into practice. The RTI Press mission is to disseminate information about RTI research, analytic tools, and technical expertise to a national and international audience. RTI Press publications are peer-reviewed by at least two independent substantive experts and one or more Press editors.

Suggested Citation

Jones, N. S., Roper-Miller, J. D., Waltke, H., McLeod-Henning, D., Weiss, D., and Barcus, H. (2017). *Proceedings of the International Forensic Radiology Research Summit May 10–11, 2016, Amsterdam, The Netherlands*. RTI Press Publication No. CP-0005-1709. Research Triangle Park, NC: RTI Press. <https://doi.org/10.3768/rtipress.2017.cp.0005.1709>

This publication is part of the
RTI Press Conference Proceedings
series.

RTI International
3040 East Cornwallis Road
PO Box 12194
Research Triangle Park, NC
27709-2194 USA

Tel: +1.919.541.6000
E-mail: rtipress@rti.org
Website: www.rti.org

©2017 RTI International. All rights reserved. This publication is protected by copyright. Credit must be provided to the author and source of the publication when the content is quoted. No part of this publication may be reproduced without permission in writing from the publisher. RTI International is a registered trademark and a trade name of Research Triangle Institute.

<https://doi.org/10.3768/rtipress.2017.cp.0005.1709>

www.rti.org/rtipress

Contents

About the Authors	i
Acknowledgments	ii
Abstract	iii
Introduction	iv
Forensic Radiology Overview	1
Landscape of the Application Of Forensic Radiology and Imaging Technologies	5
The Netherlands	6
Switzerland	6
South Africa	7
Poland	8
The United States of America	8
Challenges and Research Priorities	11
Big Data and Statistics	12
Age Estimation and Reconstruction	13
Multimodal Imaging	14
Visualization and Presentation	14
Landscape of Research and Development Grant Funding Agencies	15
The European Union	16
The Netherlands	16
Austria	16
The United States of America	17
Abstracts	18
Conclusion	19
References	21
Appendix A. International Forensic Radiology Research Summit Invitation Letter	23
Appendix B. International Forensic Radiology Research Summit Agenda	24
Appendix C. International Forensic Radiology Research Summit Attendee List	25

About the Authors

Nicole S. Jones, MS, is the associate director of the Center for Forensic Sciences at RTI International.

Jeri D. Roper-Miller, PhD, is the director of the Center for Forensic Sciences at RTI International.

Heather Waltke, MFS, MPH, is the associate director of the Office of Investigative and Forensic Sciences at the National Institute of Justice.

Danielle McLeod-Henning, MFS, is a physical scientist at the Office of Investigative and Forensic Sciences at the National Institute of Justice.

Danielle Weiss, MFS, JD, is a senior forensic analyst at Booz Allen Hamilton.

Hannah Barcus, BA, is a forensic analyst at Booz Allen Hamilton.

Acknowledgments

This work was developed in part through a Cooperative Agreement from the National Institute of Justice (2011-DN-BX-K564), Office of Justice Programs, US Department of Justice by the Forensic Technology Center of Excellence at RTI International. Opinions or points of view expressed herein represent a consensus of the authors and do not necessarily represent the official position or policies of the US Department of Justice.

The authors wish to thank Professor Rick R. van Rijn of the Academic Medical Center Department of Radiology and Past-chair of the International Society of Forensic Radiology and Imaging for his valuable input and shared coordination of the IFFRS and this proceeding. The authors also wish to recognize Dr. Natalie L. Adolphi, Research Director of the Center for Forensic Imaging University of New Mexico School of Medicine (also Associate Professor, Departments of Biochemistry and Molecular Biology, Pathology, and Radiology) for her willingness to review and provide images for the Imaging Technique Table in the Introduction.

Contents (continued)

Figures

Figure 1. Participants of the International Forensic Radiology Research Summit (Amsterdam, Netherlands)	v
Figure 2. 2016 forensic radiology and imaging research agenda	12
Figure 3. The NIJ's R&D process	17

Table

Table 1. Imaging techniques used in medicolegal applications	3
---------------------------------------------------------------------	---

Abstract

On May 10–11, 2016, the US Department of Justice (DOJ) National Institute of Justice (NIJ), the Netherlands Forensic Institute (NFI; Dutch Ministry of Security and Justice of the Netherlands), the International Society for Forensic Radiology and Imaging (ISFRI), the International Association of Forensic Radiographers (IAFR), and NIJ's Forensic Technology Center of Excellence (FTCoE) at RTI International organized and convened the International Forensic Radiology Research Summit (IFRRS) at the Academic Medical Center in Amsterdam. The summit assembled 40 international subject matter experts in forensic radiology, to include researchers, practitioners, government employees, and professional staff from 14 countries. The goal of this 2-day summit was to identify gaps, challenges, and research needs to produce a road map to success regarding the state of forensic radiology, including formulating a plan to address the obstacles to implementation of advanced imaging technologies in medicolegal investigations. These proceedings summarize the meeting's important exchange of technical and operational information, ideas, and solutions for the community and other stakeholders of forensic radiology.

Summit countries represented

Australia

Canada

Denmark

France

Germany

Ireland

Japan

Netherlands

Poland

South Africa

Switzerland

United Kingdom

United States

Introduction

In 2011, the US Department of Justice (DOJ) National Institute of Justice (NIJ) entered into a Memorandum of Understanding (MOU) with the Netherlands Forensic Institute (NFI; Dutch Ministry of Security and Justice of the Netherlands) along with the Netherlands Organization for Scientific Research, Chemical and Physical Sciences Division. The relationship aimed to advance cooperation and information sharing for the development of effective solutions and priorities that will improve forensic science and criminal justice research. In fulfillment of these efforts, the NIJ and NFI identified a mutual priority research need focusing on research and practice in forensic radiology.

In 2015, NIJ and NFI prepared to convene a working group of professionals in forensic radiology to identify gaps, challenges, and research needs to produce a road map to success regarding the state of forensic radiology internationally. On May 10–11, 2016, NIJ, NFI, the International Society for Forensic Radiology and Imaging (ISFRI), the International Association of Forensic Radiographers (IAFR), and NIJ's Forensic Technology Center of Excellence (FTCoE) at RTI International organized the International Forensic Radiology Research Summit (IFRRS) at the Academic Medical Center (AMC) in Amsterdam. The IFRRS occurred in conjunction with the Joint Congress of the International Society for Forensic Radiology and Imaging (ISFRI) and the International Association of Forensic Radiographers (IAFR) so that its purpose, goals, and initial outcomes were immediately shared with the attendees of this joint meeting.

The summit consisted of 40 researchers, practitioners, government employees, and professional staff from 13 countries (Figure 1).

These individuals were brought together to build research partnerships and encourage collaborations in the global community of forensic radiology, as well as address challenges and identify possible solutions for the implementation of these advanced imaging technologies in medicolegal practice.

During this 2-day summit, representatives focused on

- overall objectives and outcomes for the IFRRS,
- the current landscape of forensic medicine technologies,
- forensic radiology research projects and funding opportunities, and
- challenges and possible research priorities.

Participants shared experiences from their countries and began an international dialogue that addressed the current state of forensic imaging technologies, implementation barriers, research needs and priorities, and possible future opportunities for collaboration. Facilitated discussions and breakout discussion groups furthered the academic and evidence-based practice dialogue. The summit fostered an opportunity for subject-matter experts from across the

world to discuss the state of research, practice, and technology within forensic radiology. This report presents the proceedings of the IFRRS and offers additional information to help stakeholders better understand the state of the technologies and build awareness of the issues. Refer to appendixes A and B for the invitation letter and the agenda, respectively. In addition to these proceedings, the primary deliverable of the summit was a scientific article in the *Journal of Forensic Radiology and Imaging* (JoFRI) (Aalders et al., 2017).

Figure 1. Participants of the International Forensic Radiology Research Summit (Amsterdam, Netherlands)





Forensic Technology

CENTER OF EXCELLENCE

A program of the National Institute of Justice

FORENSIC RADIOLOGY OVERVIEW

Attendees discussed the various forensic radiology technologies used in postmortem examination throughout the Summit. This topic presents the information as a cohesive overview.


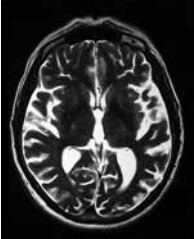
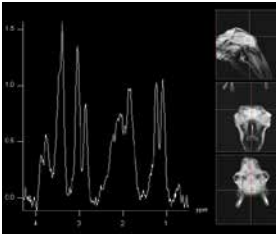

Over the past 15 years, the use of forensic radiology techniques has evolved in some parts of the world from an unstructured process of using clinical radiology and imaging for medicolegal determinations in special cases, to a recognized and specific forensic discipline within medical examiner and coroner (ME/C) offices; however, it is not yet commonplace worldwide. Diagnostic forensic imaging technologies used to complement autopsy are computed tomography (CT), magnetic resonance (MR or MRI), and X-ray radiography (Baglivo et al., 2013). In addition, other less common imaging techniques reported for medicolegal death investigations (MDI) include photogrammetry, fluoroscopic (c-arm) imaging, and angiography (Kudlas, Odle, & Kisner, 2010; Baglivo, et al., 2013). Table 1 provides a brief description of each of the imaging techniques.

Forensic imaging can produce valuable evidence for both civil and criminal trials. The most common use of forensic radiology is documenting and analyzing forensic evidence as part of the forensic medicine process. However, this technique also produces valuable evidence for the evaluation of nonaccidental injuries resulting from child abuse, elder abuse, domestic abuse, and assault (Kudlas et al., 2010). Forensic radiology can also provide valuable information for victim identification, including

indications of age; sex; stature; and other identifying information, such as indications of previous injuries or dental procedures. This information can be particularly beneficial in disaster victim identification (DVI). Some other uses of forensic radiology include the detection of foreign objects, such as drugs smuggled in packages hidden in body cavities, medically implanted devices, and bullet or weapon fragments in a victim's body.



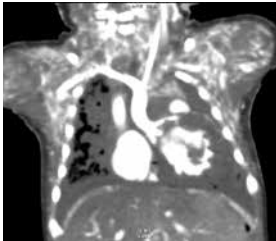
With their first publication in January 2013, JoFRI helped launch and bring to the forefront advanced imaging technology. JoFRI "aims to foster the exchange of information among forensic medicine and radiology professionals engaged in developing and utilizing imaging methods to advance non-invasive documentation and analysis of forensic findings in both living and dead persons." Today, JoFRI includes 3,904 publications. Despite these contributions to the community, additional research on three-dimensional (3D) surface documentation, 3D crime scene documentation, visualization software, postmortem angiography, postmortem biopsy, postmortem ventilation, large-scale correlations between CT and classic autopsy, MR spectroscopy metabolites, postmortem interval (PMI), time of death determination, and the use of imaging in domestic violence, mass fatality, and terrorism is needed. In addition to research on utilizing various techniques, there is a demand for research in imaging and reporting workflows, the development of less-expensive technologies, digital anthropology, and forensic imaging in the living.

Table 1. Imaging techniques used in medicolegal applications

Type and Example Image	Description	Technique (Use of Radiation)	Applications	Cost	Current Use
Computed tomography (CT) 	Uses X-rays to generate geometrically accurate 3D information about body structures. 2D cross-sectional (axial) images are first reconstructed using a computer, then reformatted to generate 2D images representing other planes or 3D surfaces or volumes. Also referred to as computed axial tomography (CAT).	Yes (yes)	<ul style="list-style-type: none"> • Whole body assessment • Trauma (e.g., spinal, thoracoabdominal, head), particularly skeletal trauma • Presence of pathological air or fluid collections • Identification of calcifications, stones • Imaging foreign objects (e.g., bullet, medical intervention) • Human identification • Skeletal remains, anthropology 	\$\$	Often (less often in the USA)
Magnetic resonance imaging (MRI) 	Imaging using a magnetic field, radio waves, and computational methods to produce geometrically accurate, detailed 2D or 3D images of soft tissues such as organs, fat, muscle, connective tissues, and body fluids.	Yes (no)	<ul style="list-style-type: none"> • Imaging soft tissues/organs in specific body regions • Trauma (e.g., spinal, thoracoabdominal, head), particularly soft tissue trauma • Assessing disease or congenital defects involving complex soft tissue structures (e.g., heart, brain) • Identification of pathological fluid or air collections • Fetal imaging 	\$\$\$	Rare
Magnetic resonance spectroscopy (MRS) 	MRS characterizes chemical composition of the tissue.	Yes (no)	<ul style="list-style-type: none"> • Measuring metabolite levels in normal vs. abnormal tissue (e.g., tumors) • Most frequently applied to the brain • Assessing post-mortem chemical changes 	\$\$\$	Very rare
X-ray radiographs 	A single image prepared through radiation exposure. Dense objects, such as bone, block the radiation and appear white in an X-ray picture.	No (yes)	<ul style="list-style-type: none"> • Document fragments, fractures • Human identification 	\$	Routine, most often

(continued)

Table 1. Imaging techniques used in medicolegal applications (*continued*)

Type and Example Image	Description	Technique (Use of Radiation)	Applications	Cost	Current Use
Photogrammetry 	Documents measurements from photographs taken at multiple angles, typically resulting in a map, drawing, or 3D model.	Yes (no)	<ul style="list-style-type: none"> • Pattern injuries (e.g., bloodstains, tire tracks) of external body surfaces • Document weapon analysis (e.g., shotgun, knife) • Document injuries to skin, bone or other surfaces • Crime scene examination • Creation of 3D models of bones for anthropology 	\$	Rare
C-arm/ fluoroscopy 	A form of radiography that captures X-rays to create a continuous image, similar to an X-ray “movie”. An alternative to CT in post-mortem imaging. C-arms can also acquire radiographs.	Yes (yes)	<ul style="list-style-type: none"> • Diagnostic trauma • Imaging of blood vessels • Pinpoint injuries • Document fragments, fractures • Imaging foreign objects (e.g., bullet) • Human identification 	\$–\$\$	Rare
Angiography 	CT or MRI performed after introducing a special fluid (“contrast media”, CM) designed to delineate the vasculature from surrounding structures; requires special equipment to circulate CM (e.g., iodine, gadolinium) through the vasculature of a deceased subject.	Yes (yes)	<ul style="list-style-type: none"> • Imaging of blood vessels, organs and heart chambers • Investigating sudden cardiac deaths, fatal hemorrhages, and vascular trauma (e.g., aneurysm, laceration, dissection, embolism) 	\$\$\$	Rare

Source: Images for this table were kindly provided by the Center for Forensic Imaging University of New Mexico School of Medicine (except for the MRI and the c-arm photos, which were provided from stock and by RTI, respectively).



LANDSCAPE OF THE APPLICATION OF FORENSIC RADIOLOGY AND IMAGING TECHNOLOGIES

At the IFRRS, various attendees presented on the international landscape and application of imaging technologies in forensic medicine within their respective countries. There is a rich diversity of research and practice in forensic radiology and imaging technologies. The IFRRS was a small group, and the information shared neither includes all countries nor all regions within a country; rather this is an international sampling. This section provides highlights from the presentations.

The Netherlands

The Netherlands Forensic Institute (NFI) is an agency of the Netherlands Ministry of Security and Justice within the Government of the Netherlands and has service level agreements with the National Police and the Public Prosecutor's Office. NFI focuses on interdisciplinary investigations spanning a range of disciplines, including forensic pathology and forensic radiology and imaging.

NFI recognizes the synergy between forensic pathology and forensic radiology and notes the increased importance of forensic radiology and forensic toxicology in the assessment of cause of death. Through the increased use of forensic radiology, NFI has decreased its average number of gross autopsies from 650 to 300, annually. International collaboration needs to continue to further develop and apply forensic radiology and research on determining PMI and the manner of death. NFI invites partners to discuss collaborative research proposals and explore the possibility of funding research projects.

Switzerland

Regions within Switzerland (Zurich, Lausanne) routinely use CT, MRI, optical 3D surface scanning, 3D photogrammetry, and postmortem CT angiography to detect and document forensic evidence as minimally invasive investigative procedures in both the living and the deceased. Within Switzerland, there are different perspectives and practices in different regions. Information shared at IFRRS primarily represented practices in a university setting in Zurich, Switzerland. Imaging

techniques supplement these investigations by contributing 3D information; these techniques do not replace the classic autopsy. In 2003, the University of Zurich started the Virtopsy® (2016) project. This project began as a multidisciplinary applied research project focused on implementing imaging modalities from diagnostic radiology and surveying technology in forensic sciences (Schweitzer, Thali, Breitbeck, & Ampanozi, 2014). As the project advanced, the Virtopsy team, in collaboration with the Austrian Center for Medical Innovation and Technology, introduced the Virtobot system as a robotic system able to perform a variety of tasks in conjunction with the CT scanner. The Virtobot system features robot-guided surface scanning for 3D documentation of the body surface to scale and in color. This documentation supplements the information captured during the external postmortem examination of the body during a conventional autopsy. The Virtobot incorporates multislice spiral CT and MRI for 3D visualization of the body to supplement the internal postmortem examination. The Virtobot also captures postmortem angiography, visualizing the cardiovascular system of the deceased with the aid of a peristaltic pump and contrast medium. In addition, the Virtobot performs both image-guided and robot-guided contamination-free tissue biopsies to obtain samples for a wide range of supplementary forensic analyses, such as histology, bacteriology, virology, toxicology, and diatomology. This procedure replaces the usual collection and storage of sample materials. The Virtobot's modular design facilitates adding future functionalities to expand the system's applications.

The Department of Forensic Imaging and Medicine of the University of Zurich's Institute of Forensic Medicine obtained quality management certification to International Organization for Standardization (ISO) 9001:2008 for all three domains—clinical, postmortem, and radiological examinations—including reporting and written expert opinions. In addition, the directors of the University Institutes have forensic imaging backgrounds. The Institute of Forensic Medicine includes 180 faculty in pharmacogenetic imaging and 40 faculty in forensic medicine and imaging, including the Virtopsy group,

which consists of a team of two to three radiologists, one technician, two 3D engineers, one medical information technician, and three forensic research doctors.

In Zurich, the impact of implementing CT scans has resulted in a 10 percent decrease of traditional autopsies and an increase in the use of screening/decision tools after external examinations. Scanning of each body occurs before a classic autopsy is performed, which allows the examiner to triage a decedent in 10 seconds and decide whether an autopsy is necessary. The main challenge in implementing CT technology was bringing together the forensic pathologist and radiologist because they do not currently work together. Now, image-based autopsies transpire in the classic autopsy room. Virtopsy accelerates the decision-making process, provides objective data archiving, and allows use of the data when seeking a second opinion. Studies indicate Virtopsy can identify 60 to 80 percent of forensically relevant causes of death consisting of a 3D surface scan, postmortem CT, postmortem MRI, postmortem CT angiography, and postmortem biopsy tissue sampling for histological, toxicological, microbiological examinations—compared to the results of forensic autopsies (Thali et al., 2003).

Studies on quality guidelines and best practices in imaging and reporting would also be valuable. Despite the volume of conducted research, obtaining funding and grants in forensic medicine in Switzerland is difficult because very few agencies are interested in investing in forensic or postmortem applications. In Switzerland, research is possible only at academic centers. Thus, the University of Zurich funds research through funds earned by providing services, donations, and small university grants, as well as through collaborative relationships with manufacturers in the scanning industry that have led to donations of supplies and equipment.

South Africa

South Africa is the 25th largest country in the world based on land area, and it is the 24th largest country based on population, with nearly 53 million people. Additionally, South Africa is highly diverse,

comprising a variety of cultures and religions and 11 officially recognized languages. Wildlife, natural challenges, crime, and violence are some of the factors that contribute to deaths requiring a medicolegal death investigation system in the country. This function is rendered by the Forensic Pathology Service.

South Africa has seven large medical schools with forensic pathology departments that conduct medicolegal death investigations in the larger metropolitan areas. Multiple smaller satellite facilities render an unnatural death investigation service throughout the rest of the country. In cases of unnatural deaths, the Inquest Act (Act 58 of 1959) mandates a medicolegal postmortem examination. The National Health Act (Act 61 of 2003) and regulations attached thereto define an unnatural death as: (a) any death due to physical or chemical influence, direct or indirect, or related complications; (b) any death, including those deaths which would normally be considered to be a death due to natural causes, which in the opinion of a medical practitioner, has been the result of an act of commission or omission which may be criminal in nature; or (c) where the death is sudden and unexpected, or unexplained, or where the cause of death is not apparent. Furthermore, section 56 of the Health Professions Act (Act 56 of 1974) completes the definition of an unnatural death as: “Death of person undergoing procedure of therapeutic, diagnostic or palliative Nature: The death of a person undergoing, or as a result of, a procedure of a therapeutic, diagnostic or palliative nature, or of which any aspect of such a procedure has been a contributory cause, shall not be deemed to be a death from natural causes as contemplated in the Inquest Act....” Large cities such as Cape Town, Johannesburg, Pretoria, and Durban can have more than 6,000 medicolegal death cases annually that require investigation.

The diversity in the caseload investigated in South Africa affords many training and research opportunities through the affiliated universities, the College of Medicine of South Africa, and the Forensic Pathology Services. Based on the profile of case admissions to Forensic Pathology

Laboratories South Africa, research priorities include sudden unexplained infant death, identification of unidentified remains, deaths in the health care setting, aviation accidents, alcohol-involved deaths, and violent crime-associated deaths. Like many other countries, South Africa faces many challenges in conducting research, including a lack of funding, heavy caseloads, and legal issues arising from cultural and religious limitations on conducting research on the deceased. Despite these limitations, research and collaboration opportunities abound, and academic forensic pathology is alive and well in the country.

Poland

In July 1943, an aircraft carrying General Władysław Sikorski (the prime minister of the Polish Government in Exile and the commander-in-chief of the Polish Armed Forces) crashed in the sea shortly after departing from the Gibraltar airport. Shortly after, a British court of inquiry investigated the crash and determined that it was an accident. However, the circumstances surrounding General Sikorski's death were controversial, leading to conspiracy theories of assassination. The Polish Institute of National Remembrance (Instytut Pamięci Narodowej; IPN) initiated a new investigation, on November 25 and 26, 2008, forensic examination including CT examination of General Sikorski's remains was conducted. After this exhumation and investigation, the use of forensic CT radiology became a common practice in Poland, starting by the Department of Forensic Medicine of Jagiellonian University in Krakow, with the use of clinical equipment. In Poland, there are currently 11 chairs of forensic medicine in public universities and immediate plans to increase the number. Benefitting from the EU funds, three departments have raw CT equipment, with the access to c-arm and portable X-ray machines or clinical CT machines in other centers. Due to EU funding policy, EU financial support prohibits financial gain from referred cases.

The 3D Analysis Laboratory at the Department of Forensic Medicine of Wrocław Medical University (n.d.) offers crime event 3D reconstruction, which maps and determines the site and course of a criminal event in a virtual 3D environment.

The United States of America

The American Society of Radiologic Technologists (ASRT) established a task force in 2007 to increase the use of radiology in forensic sciences through the development of continuing education programs. Because the use of forensic technology often lags in implementation in the United States, task force representatives visited the United Kingdom in 2008 and again in early 2009 to gain information on equipment, maintenance, forensic radiology guidelines, and protocols. The task force representatives also learned how to build an educational framework to promote the growth of forensic radiology programs (Kudlas et al., 2010). As of 2010, there were only two institutes for forensic radiology in the United States, compared with more than 100 such institutes in Europe. Most of the research in forensic radiology occurred in Europe, Scandinavia, and Japan (Kudlas et al., 2010). In 2008, ASRT conducted a survey of National Association of Medical Examiners (NAME) members, of which 88 percent indicated that they used imaging technologies in their facility. Only 14 percent had access to an onsite CT scanner, and almost 70 percent had no access to CT (Kudlas et al., 2010).

Today, the United States faces many challenges in MDI. There are nearly 2,000 US medicolegal offices and more than 450 facilities performing forensic autopsies (Hickman, Hughes, Strom, & Roper-Miller, 2007). Despite numerous articles documenting the importance of autopsy to confirm cause of death, the US national autopsy rate continues to decline. In addition, there is a national shortage of board-certified forensic pathologists (Executive Office of the President, National Science and Technology Council, 2016; National Commission on Forensic Sciences, 2015). Like many countries, the United States needs increased funding and training to obtain and use forensic imaging technologies.

The NAME Forensic Autopsy Performance Standards dictate that an autopsy shall be performed in certain circumstances (e.g., when death is unwitnessed, unexpected, unexplained, nonnatural), but allow for the pathologist's discretion regarding the need for additional dissection and laboratory testing (NAME, 2006).

The NAME performance standards define an autopsy as “An examination and dissection of a dead body by a physician for determining the cause, mechanism, or manner of death, or the seat of disease, confirming the clinical diagnosis, obtaining specimens for specialized testing, retrieving physical evidence, identifying the deceased or educating medical professionals and students.” Therefore, under the current standard, further discussions need to address the meaning of “dissection” in the NAME protocol before replacement of traditional autopsy by the virtual autopsy. Additionally, imaging and autopsy protocols must be refined. Currently, radiology can supplement the findings from external examination and gross dissection. Virtual autopsy could help with pre-autopsy triage to detect cause of death (e.g., aortic dissections, myocardial infarctions) that can be corroborated by traditional autopsy (Ross, et. al., 2012). Postmortem CT angiography combined with image-guided biopsy, because of their minimally invasive nature, have a potential role in the detection of the cause of death after acute chest pain. Some of the perceived challenges going forward will be paying for the technology, establishing the correlation between radiology and pathology, determining

whom the court will recognize as having sufficient expertise to evaluate radiographs, and establishing the admissibility of radiology in medicolegal court proceedings.

Research priorities include continuing studies investigating the radiology-pathology correlation and developing training requirements for radiologists and pathologists. The lack of funding for instrumentation and the shortage of pathologists and forensic radiologists will require that MDI offices leverage hospital-based technologies; however, improvements are beginning to occur. One possible solution could be establishing regional centers of excellence. Imaging could be used to encourage pretrial plea bargains and to avoid inflammatory evidence (e.g., graphic images) that does not apply to imaging. Additionally, with the expansion of 3D printing, 3D prints could be valuable during trials. Indeed, preliminary indicators of introduction of 3D print evidence in the court system have indicated that juries respond well to them. Similarly, there must be further research comparing CT exhibits with standard exhibits for use in court to demonstrate and assess the comprehensive nature of CT exhibits and whether they may be prejudicial.



Forensic Technology

CENTER OF EXCELLENCE

A program of the National Institute of Justice

CHALLENGES AND RESEARCH PRIORITIES

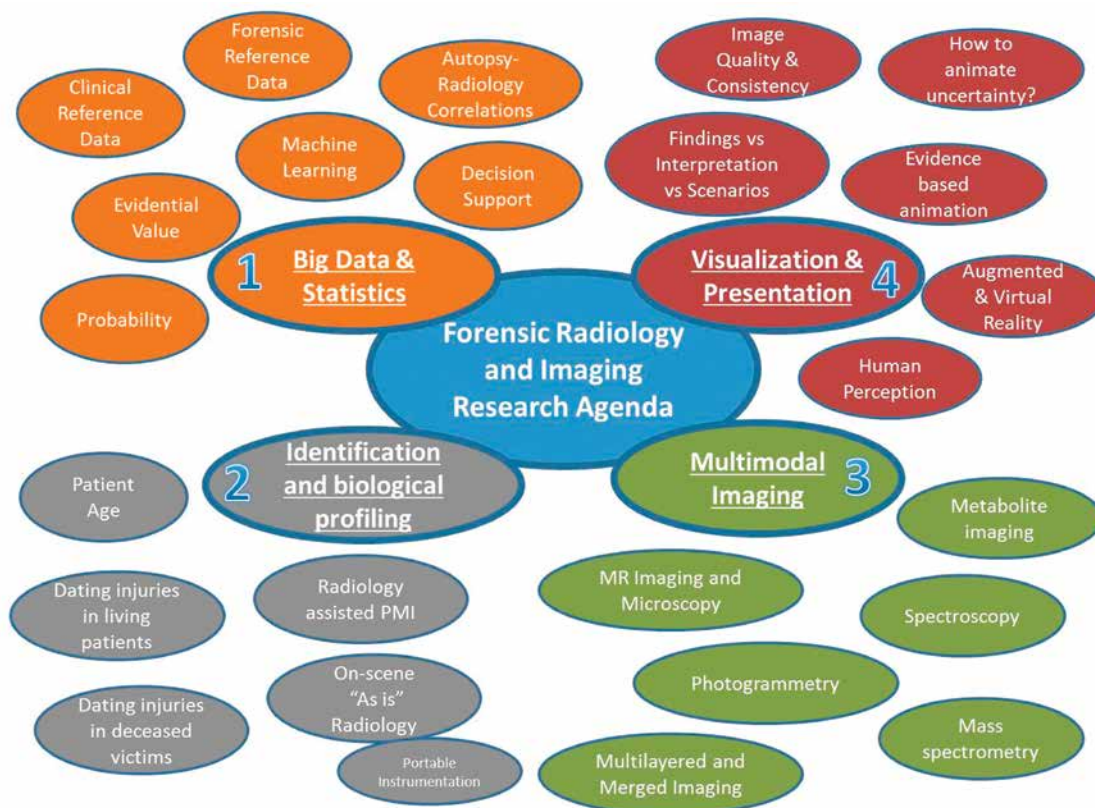
A facilitated discussion of the challenges of adopting forensic radiology techniques and research priorities led to four focal areas in building a forensic radiology and imaging research agenda: (1) big data and statistics, (2) age estimation and reconstruction, (3) multimodal imaging, and (4) visualization and presentation. Figure 2 presents a “mind map” of forensic radiology and imaging research needs and representative topics for each. In a post-summit meeting, an additional topic—quality and education—was appended.

Big Data and Statistics

Creating both international clinical and forensic reference databases for research purposes could greatly enhance the ability of individual institutions to conduct research, especially for smaller institutes and special populations for which the number of cases is insufficient to conduct a statistically relevant

study (Ruder, Thali, & Hatch, 2014). Some examples are pediatric (Addison, Authors, & Thayyil, 2014) and elder abuse cases (Daly & Fowler, 2007). There are few investigations of these types of abuse cases per institute each year; this creates one international data set to which all countries could contribute and access for research purposes (Daly & Fowler, 2007). In addition, research needs include data on scanning children and the elderly who have survived abuse, especially regarding neck injuries after strangulations and pediatric lesions from skeletal trauma. Similarly, some institutions have data from only a small cross section of ethnicities and thus, collaborating internationally would diversify the data set. Furthermore, some countries do not commonly experience certain types of homicide. For instance, gunshot wounds in the Netherlands are infrequent because of strict gun laws. In this case, collaborating with the United States would provide a larger data

Figure 2. 2016 forensic radiology and imaging research agenda



Source: Aalders et al. (2017). © 2017 Elsevier Ltd.

set to support research studies with greater statistical power and thus provide more evidence-based data for courts, thus increasing evidential value. In rare cases, increasing the size of the data set through comparison to an international database would enable an examiner to provide increased support for a medicolegal decision such as cause and manner of death.

The creation of larger data sets and the combination of big data with large collections of imaging results would help drive the development of coding to enable machine-driven automated image assessments. In diagnostic radiology, several studies have used algorithmic models to detect tumors in lungs or breasts and obtained positive results. Far fewer studies have focused on whole-body imaging, and to date, the studies on automated detection have exhibited poor selectivity and sensitivity, indicating the need for more research to perfect the algorithms. Big data sets would also help inter- and intra-observer studies document observer failure to evaluate images and identify a phenomenon accurately. Inter-observer variation (the amount observers vary relative to one another when reporting on the same material) and intra-observer variation (the amount one observer varies between observations when reporting more than once on the same material) represent two types of error, and research for probability of each type of error needs to be established to support decision making. Working groups have found that both teaching techniques and formal education vary among countries. Using big data sets would allow studies to assess the skills of radiological technologists versus autopsy technologists to determine the difference between these groups of professionals (delta) to understand whether training could improve techniques and procedures. Additionally, studies are needed to compare the abilities of radiologists and pathologists to interpret CT scans and thereby identify necessary training to improve interpretations and identify unnecessary scans for a specified type of death (e.g., gunshot injuries). Ultimately, an ideal future goal would be to develop evidence-based, gold-standard protocols within forensic medicine.

Age Estimation and Reconstruction

Population frequencies and variation to extrapolate a biological profile to estimate age, sex, stature, ancestry, and other identification characteristics need more support data to confirm their utility. For example, research on age determination in the living could help forensic pathologists distinguish stillbirth from homicide. This information would also be valuable for DVI, particularly in situations in which fingerprint collection is unavailable or DNA collection is too risky because of the biological hazards of collecting standard fluids for comparison. However, further validation studies can verify points of concordance and alignment with the information gathered through forensic imaging, fingerprints, and DNA. In many cases, conducting the investigation at the death scene is important, driving the development of more portable equipment. The United Kingdom has been using portable scanners for several years (Kudlas et al., 2010). On-scene mobile scanning could be very valuable in DVI cases.

Using CT to visualize and reconstruct body positioning warrants consideration. Research studies can identify and recommend the best position to obtain consistency and increase image quality. The position of the body at autopsy and scanning is not the same as the position of the discovered body. Moving the body could potentially alter the orientation of injuries, potentially affect the interpretation of the injuries, or even mask injuries. Transportation the body can also displace fractures. Obtaining a second opinion after an autopsy is impossible, but studying radiological images allows for an independent replication of the interpretation if changes in the body position could explain anomalies seen at autopsy. Radiology could also facilitate range-of-fire (distance of the shooter) determinations.

To accurately identify and date both antemortem and postmortem injuries, CT/MRI data to date injuries in living patients over time, in both soft tissue and hard tissue, is compared with those in the deceased. This research could be especially relevant in child abuse cases. Research on the use of MRI scanning in cases of acute myocardial infarction to estimate the age of

the infarction would also be useful. Understanding postmortem artifacts and PMI, including those caused by decomposition, also require more research and education.

Multimodal Imaging

Use of clinical radiology and imaging for diagnosis well established, but use of these techniques and attendant analytical methods for postmortem investigations warrants further exploration. Combining traditional methods of forensic medicine to identify regions of interest with novel techniques—referred to as multimodal approaches—can provide a more detailed picture of forensic applications of radiology. One example of adapting existing technologies to new applications in forensic research is by using a multimodal approach that combines MRI and MRS to cover all aspects of research and applications related to medicine and drug targeting or toxicology. MRS uses the same instrument as conventional MRI, capturing spectra as a series of tests via a second channel to measure biochemical changes in the brain and chemical metabolism within the body. Successful use of this multimodal approach transpired in cancer research, where MRI identifies the anatomical location of a tumor and MRS compares the chemical composition of normal brain tissue with that of abnormal tumor tissue (Mayfield Clinic, 2016).

Other multimodal approaches with potential forensic applications include the combination of CT and MRS, which has been successfully used to study osteoporosis and osteoarthritis (Kapadia et al., 1998), and the combination of MRI and near-infrared optical spectroscopy, which has been successfully applied to identify malignant and benign breast

tumors (Ntziachristos, Yodh, Schnall, & Chance, 2002). Similarly, various types of optical spectroscopy in scene investigation of latent and dried blood spots (Edelman, van Leeuwen, & Aalders, 2015; Laan, Bremmer, Aalders, & de Bruin, 2014) and bruising are published for forensic investigations (Edelman, Gaston, van Leeuwen, Cullen, & Aalders, 2012; Stam, et al., 2011). Defining the correlation between radiology and pathology findings such as developing methods of effectively displaying multimodal imaging or synthesizing multimodal results for presentation in court and to victims' families have reported benefit (Ruder et al., 2014).

Visualization and Presentation

Visualization is very powerful, but research is needed to assess the value of how it is presented, including research on how to visualize what is reliable, what scenarios align with the evidence, what visual aids should be used to present those scenarios to the jury, and on the impact of advanced imaging techniques. Currently, no research has addressed quantifying the utility of demonstrative aids and illustrations used in court, but evidence-based data would be beneficial to the criminal justice system. Animations are based on theory rather than documentation, and research is needed to define and present findings in relation to interpretation and possible suggested scenarios. Currently, animation provides a demonstrative aid to expert testimony, but getting animations admitted into court is difficult. For example, in the O. J. Simpson trial, an animation of how the murders occurred was not admissible because it was theoretical. These studies will become more important as the use of augmented reality through animation and simulation increases to build crime scene scenarios.



Forensic Technology
CENTER OF EXCELLENCE
A program of the National Institute of Justice

LANDSCAPE OF RESEARCH AND DEVELOPMENT GRANT FUNDING AGENCIES

Evidence-based research used in forensic postmortem investigations must continue. Although there is funding for forensic radiology, it is limited. Many agencies must choose resourceful alternatives. In the past, grant proposals in forensic radiology have endured the challenge of identifying a funding niche; for example, health care funding agencies deemed the research as too forensic in nature and forensic/criminal justice funding agencies judged the research as too clinical to qualify for funding.

Most of the basic research in forensic pathology has originated in Europe and Japan (National Academy of Science, 2009). In addition to US funding agencies—Department of Health and Human Services (HHS), National Institutes of Health (NIH), Department of Justice (DOJ), Department of Defense (DOD), and Department of Homeland Security (DHS)—there are several funding agencies supporting scientific research within the European Union, including Horizon 2020; the Netherlands, including ZonMw and the Kinderpostzegels Organization; and Austria, including the Ludwig Boltzmann Gesellschaft (LBG). This section summarizes the current funding of R&D in forensic radiology.

The European Union

Horizon 2020 is the largest research and innovation program in the European Union, with €80 billion in total funding available for 2014–2020. Horizon 2020 focuses on promoting innovative research through excellent science to tackle societal challenges. This program has a budget of €378 million for the period of 2014–2020 (€54 million annually on average, corresponding to less than 1 percent of total funding) set aside for the Ministry of Security and Justice Program, focusing on the following key areas (European Commission, 2014):

- Judicial cooperation in civil matters, including civil and commercial matters, insolvencies, family matters and successions;
- Judicial cooperation in criminal matters;
- Judicial training, including language training on legal terminology, with a view to fostering a common legal and judicial culture;

- Effective access to justice in Europe, including rights of victims of crime and procedural rights in criminal proceedings; and
- Initiatives in the field of drugs policy (judicial cooperation and crime-prevention aspects).

The Netherlands

The Ministry of Health, Welfare and Sport and the Netherlands Organization for Scientific Research commissioned the ZonMw to fund research to improve health care in the Netherlands. The ZonMw works with experts in the field to identify the current state of health care, identify issues, set research priorities, and identify solutions. The ZonMw incorporates these recommendations into a grant-funding program to set the direction of scientific and health care research to promote R&D and implementation. The ZonMw does not currently have a program targeting forensic medicine, radiology, or imaging; however, proposals with scientific validity that leverage adjacent technologies or complimentary areas of research needs are potential topics for funding.

In addition to the ZonMw, the Netherlands also has the Kinderpostzegels Organization, which is the Dutch organization to support the “development of vulnerable children, wherever they are in the world” (Kinderpostzegels, n.d.). The Kinderpostzegels Organization has three programs focusing on education, alternative care, and children and trauma. Although the Kinderpostzegels Organization supports programs in trauma, securing funding for programs in forensic imaging remains difficult.

Austria

The Ludwig Boltzmann Gesellschaft (LBG) is Austria’s independent research agency focusing on improving the health sciences, to advance society and promote innovation (Ludwig Boltzmann Gesellschaft, 2016). LBG currently operates 16 research institutes and clusters with more than 600 employees, including the Ludwig Boltzmann Institute for Clinical Forensic Imaging (LBI-CFI), an organization established in June 2008. LBI-CFI focuses its research efforts on forensic radiology with the goal of convening an interdisciplinary research team to develop basic

parameters for the clinical-forensic use of MRI and CT. LBI-CFI works to improve the results of forensic examinations and extend the impact of experts' reports to create a broader basis of objectively collected data, including internal injuries, to increase legal security and establish radiological methods as standard procedures in forensic examinations (Ludwig Boltzmann Gesellschaft, 2016). In 2015, the annual operating budget for LBI-CFI was €1.3 million (Ludwig Boltzmann Institute, 2015). LBI-CFI collaborates with the Medical University of Graz to run a Clinical-Forensic Outpatient Center, which is an investigative body for victims of sexual violence, child abuse, or maltreatment. In this center, forensic medical experts thoroughly examine patients and provide documentation of injuries, collect and secure forensic evidence, and provide expert testimony or reports to support the investigation.

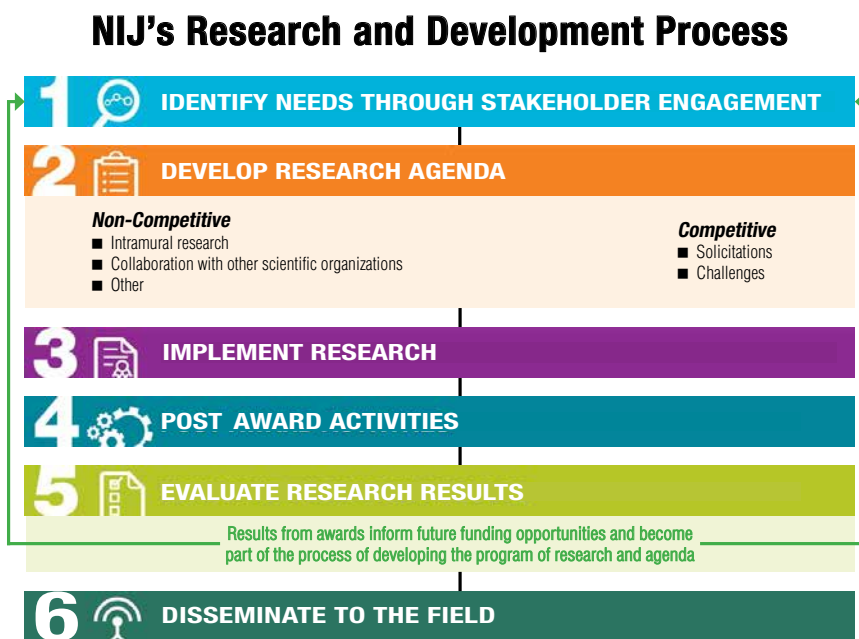
The organizational structure of LBI-CFI promotes collaboration among researchers and practitioners from the fields of forensic medicine, medical technology, medical physics, legal science, and judicature, who work to lay a foundation for creating a global standard regarding the use of CT and MRI

in clinical-forensic medicine (LBI-CFI, 2016). In 2015, LBI-CFI produced 31 presentations, 8 PhD dissertations, and 19 peer-reviewed publications, including 8 books or book chapters (Ludwig Boltzmann Institute, 2015).

The United States of America

The NIJ's Office of Investigative and Forensic Sciences (OIFS) is the federal government's principal agency for forensic science research and development. OIFS's activities include supporting research and development, technology transition, and capacity building and technical assistance. NIJ funds research and development to provide objective, independent, evidence-based knowledge and tools to meet the challenges within the criminal justice system, particularly at the state and local levels. Funding is available to all forensic disciplines, including forensic pathology. Figure 3 provides the basic steps of the NIJ's R&D process for evaluating research for funding. This funding can support personnel, travel (to execute research or dissemination), supplies, equipment, subcontracts to partnering agencies, consultants, and tuition.

Figure 3. The NIJ's R&D process



Source: Reproduced with permission from the National Institute of Justice (<https://www.nij.gov/Documents/nij-research-and-development-process-high-level.pdf>).

In 2016, NIJ provided more than \$24 million in R&D funding in Forensic Science for Criminal Justice Purposes supporting 54 awards. Since 1995, NIJ has published an annual report to Congress summarizing its forensic science R&D program pursuant to Title 1 of the Omnibus Crime Control and Safe Streets Act of 1968 and Title II of the Homeland Security Act of 2002 (NIJ, 2014).

At the IFRRS, summaries of NIJ supported research being conducted at the University of New Mexico Health Science Center (UNMHSC) were presented. More information on NIJ funded research in forensic pathology can be found on NIJ's website (NIJ, 2017).

Abstracts

2010-DN-BX-K205: Utility of Postmortem X-ray Computed Tomography (CT) in Supplanting or Supplementing Medicolegal Autopsies

In 2010, UNMHSC began a 4-year study with four cohorts (blunt force injuries, childhood traumatic fatalities, gunshot injuries, drug poisonings) investigating research questions to investigate the ability of CT technology to supplant or supplement traditional gross autopsy. In each case, the maximal injury score (MAIS) was determined in each region. Case enrollment of more than 890 cases were completed, and congruence in the cause of death (COD) determined by a forensic pathologist and forensic radiology technologies was achieved in 85 percent of the cases. Among noncongruent cases, for 10 percent, the pathologists were incorrect; for 4 percent, the radiologists were incorrect; and for 1 percent, both the pathologists and radiologists were incorrect. Based on these research findings, CT can supplement or supplant autopsy. The final report is available online at the National Criminal Justice Reference Service (Lathrop & Nolte, 2016).

2012-DN-BX-K019: Investigation of the Impact of Body Temperature and Postmortem Interval on Magnetic Resonance Imaging (MRI) of Unfixed Tissue

This NIJ research project began in 2012. It investigates the effect of temperature as a PM variable on MRI in a thorough and systematic manner. The cooler body temperature occurring after death relative to that of live subjects ($98.6 \pm 1^\circ\text{F}$ [$37 \pm 0.6^\circ\text{C}$]) is expected to affect MRI results. This research utilizes biopsied tissue from an animal model and involves three phases. In phase 1, the tissue-specific MR parameters T1 and T2 (the initial and final temperature-dependent relaxation times) and the apparent diffusion coefficient (ADC) as a function of temperature will be measured for a

variety of mammalian tissues (Ruder et al., 2014). The findings of phase 1 will guide phase 2. Phase 2 will identify the tissue parameters used as noninvasive thermometers, which are essential for optimizing imaging with respect to the sample temperature. Based on this knowledge, a generic procedure for improving postmortem MRI protocols to develop and validate in studies of animals and human decedents. In phase 3, the impact of the postmortem interval (PMI) and decomposition temperature on tissue-specific MR parameters will be studied using intact animals. This project is ongoing.

2013-DN-BX-K004: Investigation of Postmortem Magnetic Resonance Imaging for the Detection of Intraneural Hemorrhage

This research investigates the utility of postmortem MR for detecting intraneural hemorrhage. Utilizing this technique could represent a significant technological advance in investigations of deaths with pediatric spinal injury, alternative mechanisms involved in shaking injury, and severe hyperflexion/hyperextension. Hyperflexion is particularly interesting because it is an occult injury typically not identified during autopsy because it is difficult to dissect. This study also consists of three phases. Phase 1 seeks to optimize the signal-to-noise ratio (coil uniformity) using a three-dimensional (3D) model of infants at 3, 6, and 12 months of age with a tube in the cervical location. Phase 2 focuses on the optimization of the contrast-to-noise ratio (maximum contrast) by injecting bovine blood into neural tissue for observation. In the final phase, an animal model will be injected with blood and the temporal changes in the blood (i.e., hemorrhage at various times) will be monitored. Ideally, this research will inspire a paradigm shift towards employing reasonable forensic protocols to detect effectively these injuries with postmortem MR.



Forensic Technology
CENTER OF EXCELLENCE

A program of the National Institute of Justice

CONCLUSION

The application of advanced imaging technologies in postmortem examination performed as part of the medicolegal death investigation represents a paradigm shift from traditional methods and procedures for determining cause and manner of death. Dialogue among researchers and early adopters is essential for this to occur. The International Forensic Radiology Research Summit was a venue to

communicate knowledge and needs from across the globe. Topics such as research gaps, education and training, funding opportunities, and challenges to implementation of practice are among the important issues covered during this event. Attendees of the IFRRS continue to advance the purpose and goals of this event.

REFERENCES

- Aalders, M. C., Adolphi, N. L., Daly, B., Davis, G. G., de Boer, H. H., Decker, S. J., . . . Wozniak, K. (2017, April). Research in forensic radiology and imaging; identifying the most important issues. *Journal of Forensic Radiology and Imaging*. <https://doi.org/10.1016/j.jofri.2017.01.004>
- Addison, S., Authors, O., & Thayyil, S. (2014, April). Post-mortem MRI as an alternative to non-forensic autopsy in fetuses and children: From research into clinical practice. *British Journal of Radiology*, 87(1036), 20130621. <https://doi.org/10.1259/bjr.20130621>
- Baglivo, M., Winklhofer, S., Hatch, G. M., Ampanozi, G., Thali, M. J., & Ruder, T. D. (2013). The rise of forensic and post-mortem radiology—Analysis of the literature between the year 2000 and 2011. *Journal of Forensic Radiology and Imaging*, 1(1), 3–9. <https://doi.org/10.1016/j.jofri.2012.10.003>
- Daly, B., & Fowler, D. (2007). *Utility of whole-body CT imaging in the post mortem detection of elder abuse and neglect in Maryland, 2007 (ICPSR 34201)*. National Archive of Criminal Justice Data. Retrieved November 1, 2016, from <http://www.icpsr.umich.edu/icpsrweb/NACJD/studies/34201>
- Department of Forensic Medicine of Wrocław Medical University. (n.d.). *3D Analysis Laboratory*. Retrieved June 15, 2016, from <http://www.medlab3d.umed.wroc.pl/laboratory.html>
- Edelman, G. J., Gaston, E., van Leeuwen, T. G., Cullen, P. J., & Aalders, M. C. (2012, November 30). Hyperspectral imaging for non-contact analysis of forensic traces. *Forensic Science International*, 223(1–3), 28–39.
- Edelman, G. J., van Leeuwen, T. G., & Aalders, M. C. (2015, January). Visualization of latent blood stains using visible reflectance hyperspectral imaging and chemometrics. *Journal of Forensic Sciences*, 60(1), S188–S192.
- European Commission. (2014). *Horizon 2020*. Retrieved May 25, 2016, from <https://ec.europa.eu/programmes/horizon2020/>
- Executive Office of the President, National Science and Technology Council. (2016). *Strengthening the medicolegal-death-investigation system: Improving data systems*. Retrieved July 13, 2017, from https://obamawhitehouse.archives.gov/sites/default/files/microsites/ostp/NSTC/strengthening_the_medicolegal_death_investigation_system_final.pdf
- Hickman M. J., Hughes K. A., Strom K. J., & Roperomiller J. D. (2007, June). *Bureau of Justice Statistics special report: Medical examiners and coroners' offices, 2004* (US Department of Justice, Office of Justice Programs, NCJ 216756). Retrieved July 13, 2017, from <https://www.bjs.gov/content/pub/pdf/meco04.pdf>
- Kapadia, R. D., Stroup, G. B., Badger, A. M., Koller, B., Levin, J. M., Coatney, R. W., . . . Gowen, M. (1998, December 6). Applications of micro-CT and MR microscopy to study pre-clinical models of osteoporosis and osteoarthritis. *Technology and Health Care*, 5(6), pp. 361–372.
- Kinderpostzegels. (n.d.). *Kinderpostzegels voor Kinderen door Kinderen*. Retrieved June 15, 2016, from <https://www.kinderpostzegels.nl/en>
- Kudlas, M., Odle, T., & Kisner, L. (2010, March 25). *The state of forensic radiography in the United States*. Retrieved June 15, 2016, from https://www.asrt.org/docs/default-source/whitepapers/forensic_radiography_white_paperfin.pdf?sfvrsn=2
- Laan, N., Bremmer, R. H., Aalders, M. C., & de Bruin, K. G. (2014). Volume of determination of fresh and dried bloodstains by means of optical coherence tomography. *Journal of Forensic Sciences*, 59(1), 34–41.

- Lathrop, S. L., & Nolte, K. B. (2016). *Utility of postmortem X-ray computed*. Retrieved November 1, 2016, from <https://www.ncjrs.gov/pdffiles1/nij/grants/249949.pdf>
- LBI-CFI. (2016). *Structure of the Insitute of Ludwig Boltzmann Institute for Clinical-Forensic Imaging*. Retrieved November 1, 2016, from <http://cfi.lbg.ac.at/en>
- Ludwig Boltzmann Gesellschaft. (2016, May 25). *Research for people*. Retrieved May 25, 2016, from <http://www.lbg.ac.at/en>
- Ludwig Boltzmann Institute. (2015). *2015 annual report of the Ludwig Boltzmann Institute for Clinical Forensic Imaging*. Graz, Austria: Ludwig Boltzmann Institute for Clinical-Forensic Imaging.
- Mayfield Clinic. (2016, June 15). *Magnetic resonance (MR) spectroscopy*. Retrieved on July 13, 2017, from <http://www.mayfieldclinic.com/PE-MRspectroscopy.htm>
- National Academy of Science. (2009). *Strengthening forensic science in the United States: A path forward*. National Academies' National Research Council. Washington DC: National Academies Press.
- National Association of Medical Examiners (NAME). (2004). *Preliminary report on America's medicolegal offices* (National Insitute of Justice, Forensic Summit). Washington, DC: National Criminal Justice Reference Service.
- NAME. (2006). *Forensic autopsy performance standards*. San Antonio, TX: NAME.
- National Commission on Forensic Sciences. (August 10-11, 2015). *Views document on increasing the number, retention, and quality of board-certified forensic pathologists*. Retrieved July 13, 2017, from <https://www.justice.gov/ncfs/file/787356/download>.
- National Institute of Justice. (2014). *National Institute of Justice annual report*. Retrieved July 25, 2017, from <https://www.ncjrs.gov/pdffiles1/nij/249533.pdf>
- National Institute of Justice. (2017). *Forensic pathology*. Retrieved June 1, 2017, from <https://www.nij.gov/topics/forensics/evidence/pathology/pages/welcome.aspx>
- Ntziachristos, V., Yodh, A. G., Schnall, M. D., & Chance, B. (2002, July). MRI-guided diffuse optical spectroscopy of malignant and benign breast lesions. *Neoplasia*, 4(4), 347–354.
- Ross, S. G., Thali, M. J., Bolliger, S., Germerott, T., Ruder, T. D., & Flach, P. M. (2012). Sudden death after chest pain: Feasibility of virtual autopsy with postmortem CT angiography and biopsy. *Radiology*, 264(1), 250–259. <https://doi.org/10.1148/radiol.12092415>.
- Ruder, T. D., Thali, M. J., & Hatch, G. M. (2014). Essentials of forensic post-mortem MR imaging in adults. *British Journal of Radiology*, 87(1036), 20130567. <https://doi.org/10.1259/bjr.20130567>
- Schweitzer, W., Thali, M., Breitbeck, R., & Ampanozi, G. (2014, February 7). *Virtopsy*. Retrieved May 31, 2016, from <http://www.virtopsy.com/images/articles/virtopsycommentary2014.pdf>
- Stam, B., van Gemert, M. J., van Leeuwen, T. G., Teeuw, A. H., van der Wal, A. C., & Aalders, M. C. (2011, October). Can color inhomogeneity of bruises be used to establish their age? *Journal of Biophotonics*, 4(10), 759–767.
- Thali, M. J., Yen, K., Schweitzer, W., Vock, P., Boesch, C., Ozdoba, C., . . . Dirnhofer, R. (2003). Virtopsy, a new imaging horizon in forensic pathology: virtual autopsy by postmortem multislice computed tomography (MSCT) and magnetic resonance imaging (MRI)—a feasibility study. *Journal of Forensic Science*, 48(2), 386–403.
- Virtopsy. (2016). *About Virtopsy*. Retrieved July 17, 2017, from <http://virtopsy.com/about-virtopsy/>

APPENDIX A

International Forensic Radiology Research Summit Invitation Letter

On behalf of the National Institute of Justice (NIJ), the research, development and evaluation agency for the U.S. Department of Justice, the Netherlands Forensic Institute (NFI), an agency of the Dutch Ministry of Security and Justice, the International Society for Forensic Radiology and Imaging (ISFRI), and the International Association of Forensic Radiographers (IAFR), we are pleased to invite you to participate in the *International Forensic Radiology Research Summit*.

The purpose of this summit is to bring together professionals in the forensic radiology field to discuss the state of the art in research and practice, identify gaps and challenges, and formulate a plan to address those gaps and challenges. This summit will bring together leading forensic pathologists, radiologists, forensic scientists and researchers from around the world to collaborate and develop a roadmap to success. A detailed agenda together with additional information will be sent to the attendees in advance of the meeting.

Due to your extensive knowledge and experience in this field of expertise, you have been selected to participate in this Summit. The 2-day meeting will be held at the AMC in Amsterdam, The Netherlands on **May 10-11, 2016**. This Summit will immediately precede the ISFRI/IAFR 2016 Joint Congress being held May 12-14, 2016.

Please RSVP to Danielle McLeod-Henning, NIJ Forensic Science R&D Program Manager, at danielle.mcleod-henning@usdoj.gov no later than **March 17, 2016** if you will be able to participate.

Please save the date as we look forward to seeing you in May. If you have any questions or concerns, please contact, Danielle McLeod-Henning.

Best regards,

NIJ: Gerald LaPorte, Director, Office of Investigative and Forensic Sciences, National Institute of Justice, Department of Justice, United States of America

NFI: Prof. Arian C. van Asten, PhD, R&D Coordination, Dr. Wim Heijnen, PhD, NFI Board Member, Netherlands Forensic Institute, The Hague, The Netherlands

ISFRI: Prof. Rick R. van Rijn, MD. PhD.

IAFR: Mr. M. Viner, FCR, MSc, HDCR, DipHSM, DipFMS, DipFHID, MFSSoc, RFP, CertRP

Important Note – This Summit is still pending necessary Department of Justice conference approval. Invited attendees will be contacted by our meeting coordinator once official approval is granted.

APPENDIX B

International Forensic Radiology Research Summit Agenda



International Forensic Radiology Research Summit May 10-11, 2016 Amsterdam, The Netherlands



Netherlands Forensic Institute
Ministry of Security and Justice



DAY 1 – Tuesday, May 10, 2016

- 10:00-10:30 **Welcome Remarks**
- Dr. Wim Heijnen, Acting Vice Director, Netherlands Forensic Institute
 - Heather Waltke, Associate Director, Office of Investigative and Forensic Sciences, National Institute of Justice, US Department of Justice
- 10:30-10:45 **Introductions**
- 10:45-11:05 **Presentation:** Objectives and Aims of the International Forensic Radiology Research Summit
- Rick R. van Rijn, Chair, International Society for Forensic Radiology and Imaging
- 11:05-11:45 **Presentation:** Landscape of Forensic Medicine Technologies: Challenges and Research Priorities (20 minute presentations)
- Switzerland
 - South Africa
- 1:45-1:00 **Lunch – Provided by Co van Ledden-Hulsebosch Center for Forensic Research**
- 1:00-1:40 **Presentation:** Landscape of Forensic Medicine Technologies: Challenges and Research Priorities (20 minute presentations)
- United States
 - Japan
- 1:40-4:40 **Facilitated Discussion:** Challenges and Research Priorities
- Greg Davis, Chief Coroner/Medical Examiner Jefferson County, Alabama, U.S
- 4:40-5:00 **End of Day 1:** Remarks and Reminders
- 7:30pm **Dinner – Hosted by the Netherlands Forensic Institute**

DAY 2 – Wednesday, May 11, 2016

- 8:30-9:15 **Presentation:**
- 8:30-8:45: National Institute of Justice's Office of Investigative and Forensic Sciences R&D Portfolio, Danielle McLeod-Henning, Program Manager
 - 8:45-9:15: Highlight of NIJ-funded Forensic Radiology Research Projects
- 9:15-11:45 **Breakout:** Discussion Groups (4 discussion groups)
- 11:45-12:45 **Presentation:**
- Group Presentations (15 minute presentations)
- 12:45-1:45 **Lunch – Provided by International Society for Forensic Radiology and Imaging and the International Association of Forensic Radiographers**
- 1:45-2:00 **End of Day 2:** Closing Remarks

APPENDIX C

International Forensic Radiology Research Summit Attendee List

Maurice Aalders, PhD

Professor of Forensic Biophysics at
UvA
Co-Director of the Co van Ledden-
Hulsebosch Institute for Forensic
Science
Amsterdam, Netherlands

Natalie Adolphi, PhD

Research Associate Professor
Radiology-Pathology Center for
Forensic Imaging
New Mexico Office of the Medical
Investigator
Albuquerque, New Mexico, USA

**Owen Arthurs, BA, MA (Cantab),
MB BChir, MRCPCH, FRCR, PhD**

Academic Consultant Pediatric
Radiologist
Great Ormond Street
London, United Kingdom

Hannah Barcus, BA

Sr. Consultant, Booz Allen Hamilton
Forensic Consultant (NIJ)
Washington, DC, USA

Barry Daly, MD

Professor and Vice Chair
Research Department of Diagnostic
Radiology and Nuclear Medicine
University of Maryland School of
Medicine
Baltimore, Maryland, USA

Gregory Davis, MD

Chief Medical Examiner
Jefferson County Coroner/Medical
Examiner's Office
Director, University of Alabama
Department of Pathology, Forensic
Division
Birmingham, Alabama, USA

Hans de Boer, MD, PhD

Pathology Resident
Academic Medical Center (AMC)
Universiteit Leiden
Amsterdam, Netherlands

Summer Decker, PhD

Assistant Professor of Radiology
University of South Florida
Morsani College of Medicine
Tampa, Florida, USA

Johan Dempers, MD

Division of Forensic Medicine and
Pathology,
Department of Pathology and
Western Cape Forensic Pathology
Health Services
Faculty of Medicine and Health
Sciences,
Stellenbosch University
Tygerberg, South Africa

David Fowler

Chief Medical Examiner
State of Maryland Office of the Chief
Medical Examiner
Baltimore, Maryland, USA

**Chandra Gerrard, BS, RT(R)(CT)
(MR)(QM)**

Supervisor of Forensic Imaging, CFI
Clinical Radiology Research
Technologist
Vice-Chair and USA Liaison to the
International Association of Forensic
Radiology
University of New Mexico Health
Sciences Center
Albuquerque, New Mexico, USA

Gary Hatch, MD

Assistant Director of Radiology-
Pathology
Center for Forensic Imaging
New Mexico Office of the Medical
Investigator
University of New Mexico School of
Medicine
Albuquerque, New Mexico, USA

Paul Hofman, MD, PhD

Head of the Department of Pathology
University of Nice Sophia Antipolis
Nice, France

Hideki Hyodoh, MD

Department of Legal Medicine
Department of Radiology
Sapporo Medical University
School of Medicine
Sapporo, Japan

Morio Iino, MD, PhD

Division of Legal Medicine
Tottori University School of Medicine
Yonago, Japan

Christina Jacobsen, MD, PhD

Deputy Chief Forensic Pathologist
University of Copenhagen
Department of Forensic Medicine,
Forensic Pathology Section
Copenhagen, Denmark

Nicole Jones, MS

Associate Director
Center for Forensic Sciences
RTI International
Research Triangle Park, North
Carolina, USA

Bela Kubat, MD

Netherlands Forensic Institute
Hague, Netherlands

Peter Leth, MD, PhD

Professor, Forensic Pathology
University of Southern Denmark
Institute of Forensic Medicine
Odense, Denmark

Danielle McLeod-Henning, MSFS

Program Manager
National Institute of Justice
Office of Investigative and Forensic
Sciences
Washington, DC, USA

Edward Mazuchowski, MD, PhD

Lieutenant Coronel
US Air Force Medical Corps
Armed Forces Medical Examiner
System
Dover Airforce Base
Dover, Delaware, USA

Jonathan McNulty, MD, PhD

Associate Dean
University College of Dublin
School of Medicine
Dublin, Ireland

Kurt Nolte, MD

Chief Medical Investigator
Professor of Pathology and Radiology
University of New Mexico
Office of the Medical Investigator
Albuquerque, New Mexico, USA

**Chris O'Donnell, MBBS, M.Med,
FRANZCR, Grad. Dip. for Med.**

Forensic Radiologist
Victorian Institute of Forensic
Medicine (VIFM)
Adjunct Senior Lecturer
Department of Forensic Medicine,
Monash University
Melbourne, Victoria, Australia

Thomas Ruder, MD

Radiologist at the University Hospital
of Berne
Forensic Radiologist
Institute of Forensic Medicine
University of Zurich
Zurich, Switzerland

**Guy N. Rutty, MBE, MBBS,
FRCPath, DipRCPPath (forensic),
FFFLM, FCSFS, AFHEA**

Chief Forensic Pathologis
East Midlands Forensic
Pathology Unit
University of Leicester
Robert Kilpatrick Building
Leicester Royal Infirmary
Leicester, UK

Michael J. Thali, MD, EMBA

Professor and Chair
Institute of Forensic Medicine
University of Zurich
Zurich, Switzerland

Arian van Asten, PhD

Co-Director of the CLHC-
Amsterdam Center for Forensic
Science and Medicine
University of Amsterdam
Head of Department
Netherlands Forensic Institute
Hague, Netherlands

Rick R. van Rijn, MD, PhD

Department of Radiology
Emma Children's Hospital
Academic Medical Center
Amsterdam, The Netherlands

Heather Waltke, MFS, MPH

Associate Director
National Institute of Justice
Office of Investigative and Forensic
Sciences
Washington, DC, USA

Danielle Weiss, JD, MFS

Lead Associate, Booz Allen Hamilton
Senior-Level Policy and Strategy
Consultant (NIJ)
Washington, DC, USA

Krzysztof Wozniak, MD

Associate Professor
Chair of the Department of Forensic
Medicine
Jagiellonian University Medical
College
Kraków, Poland

Maiko Yoshida, MD

Department of Legal Medicine
Chiba University Graduate School of
Medicine
Chiba, Japan

RTI International is an independent, nonprofit research institute dedicated to improving the human condition. Clients rely on us to answer questions that demand an objective and multidisciplinary approach—one that integrates expertise across the social and laboratory sciences, engineering, and international development. We believe in the promise of science, and we are inspired every day to deliver on that promise for the good of people, communities, and businesses around the world.

The RTI Press complements traditional publication outlets by providing another way for RTI researchers to disseminate the knowledge they generate. This PDF document is offered as a public service of RTI International.